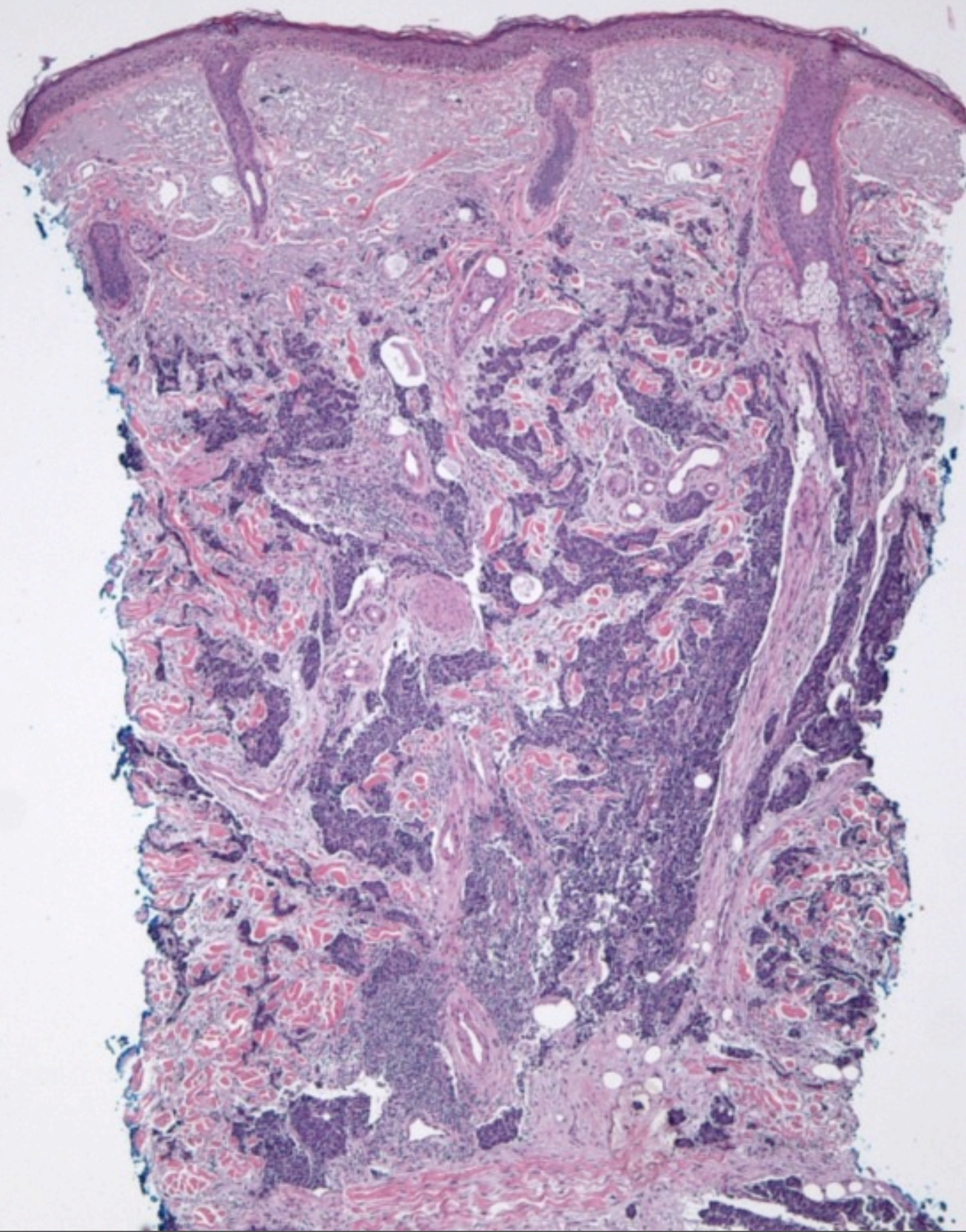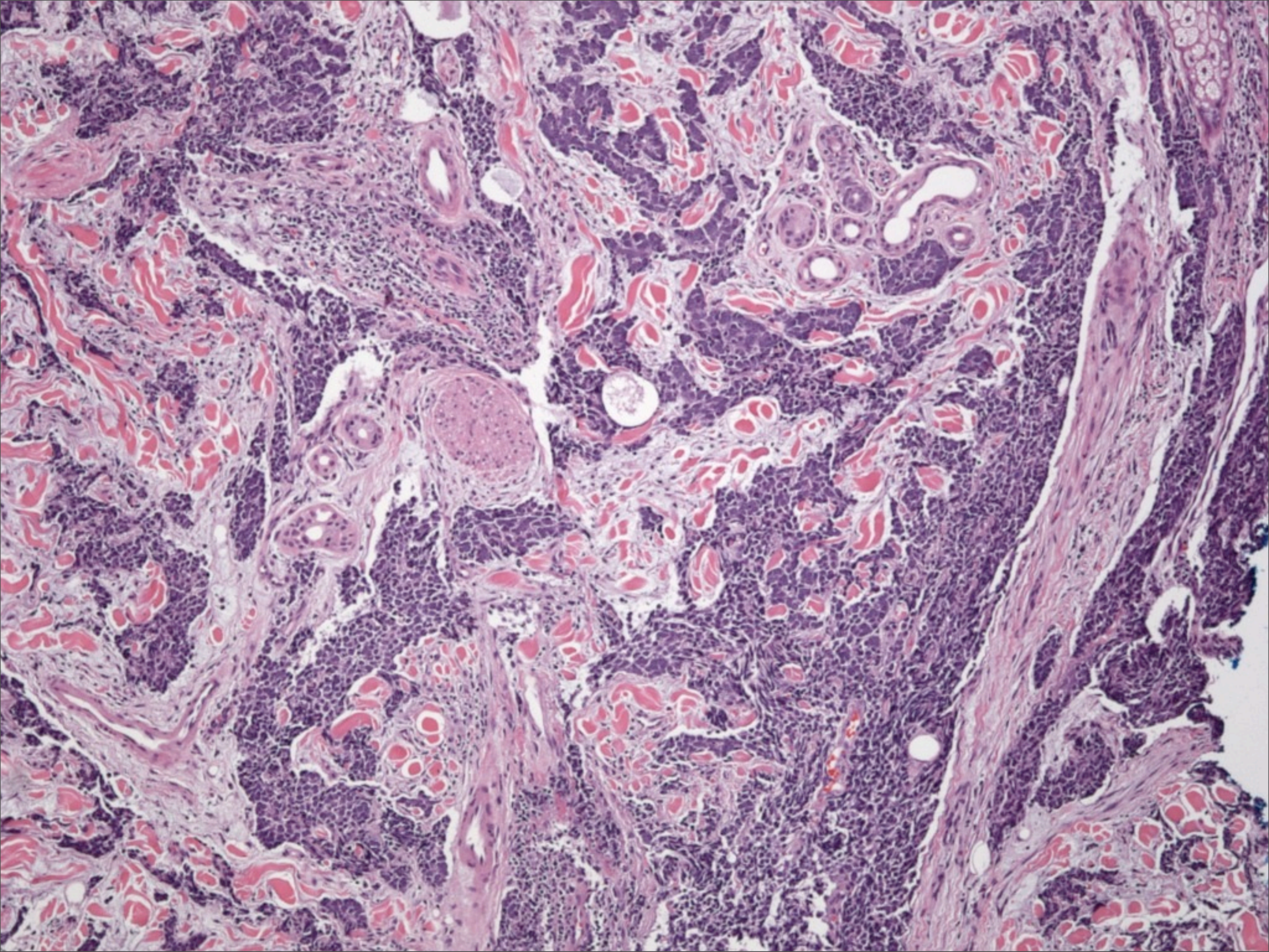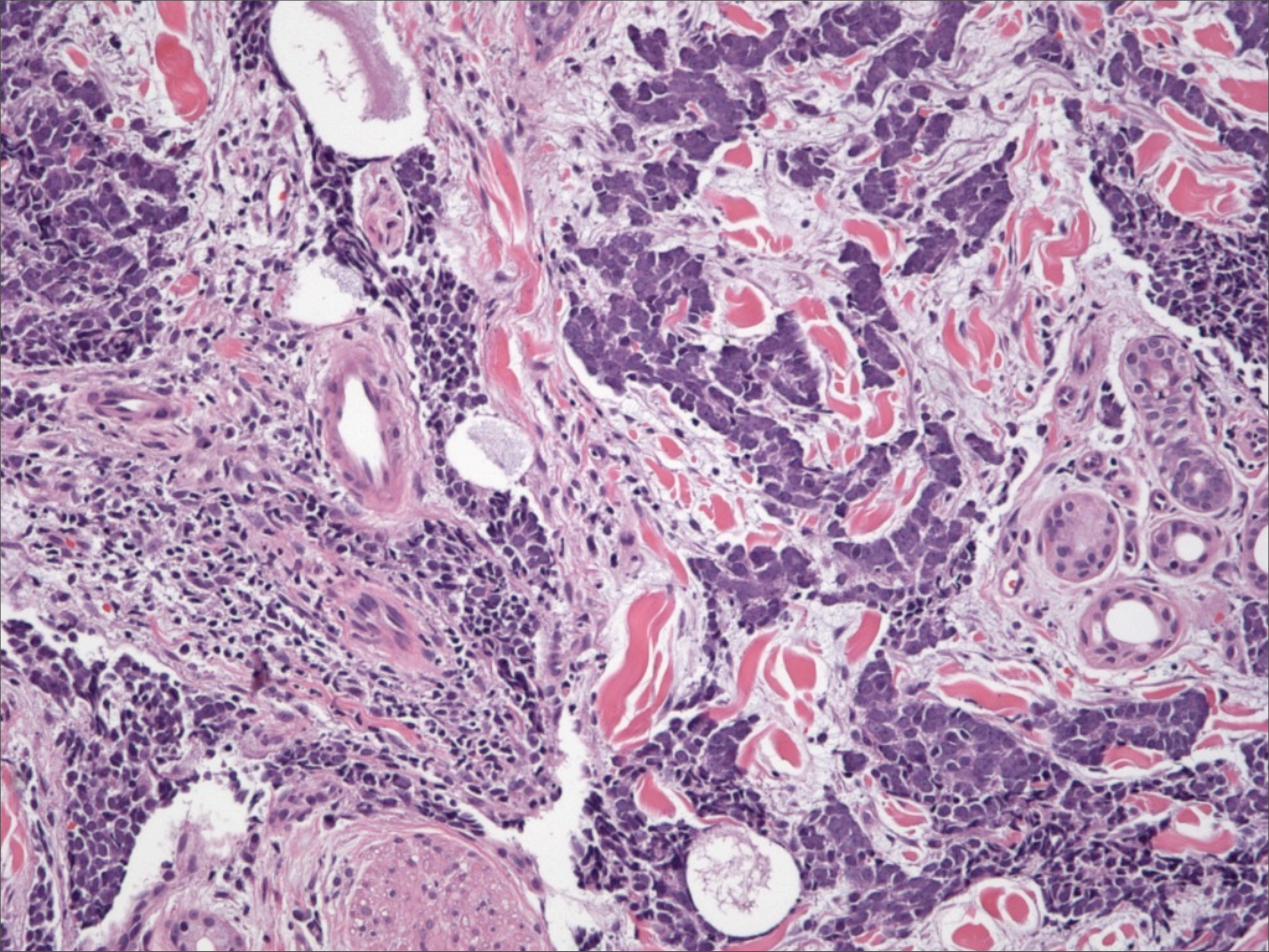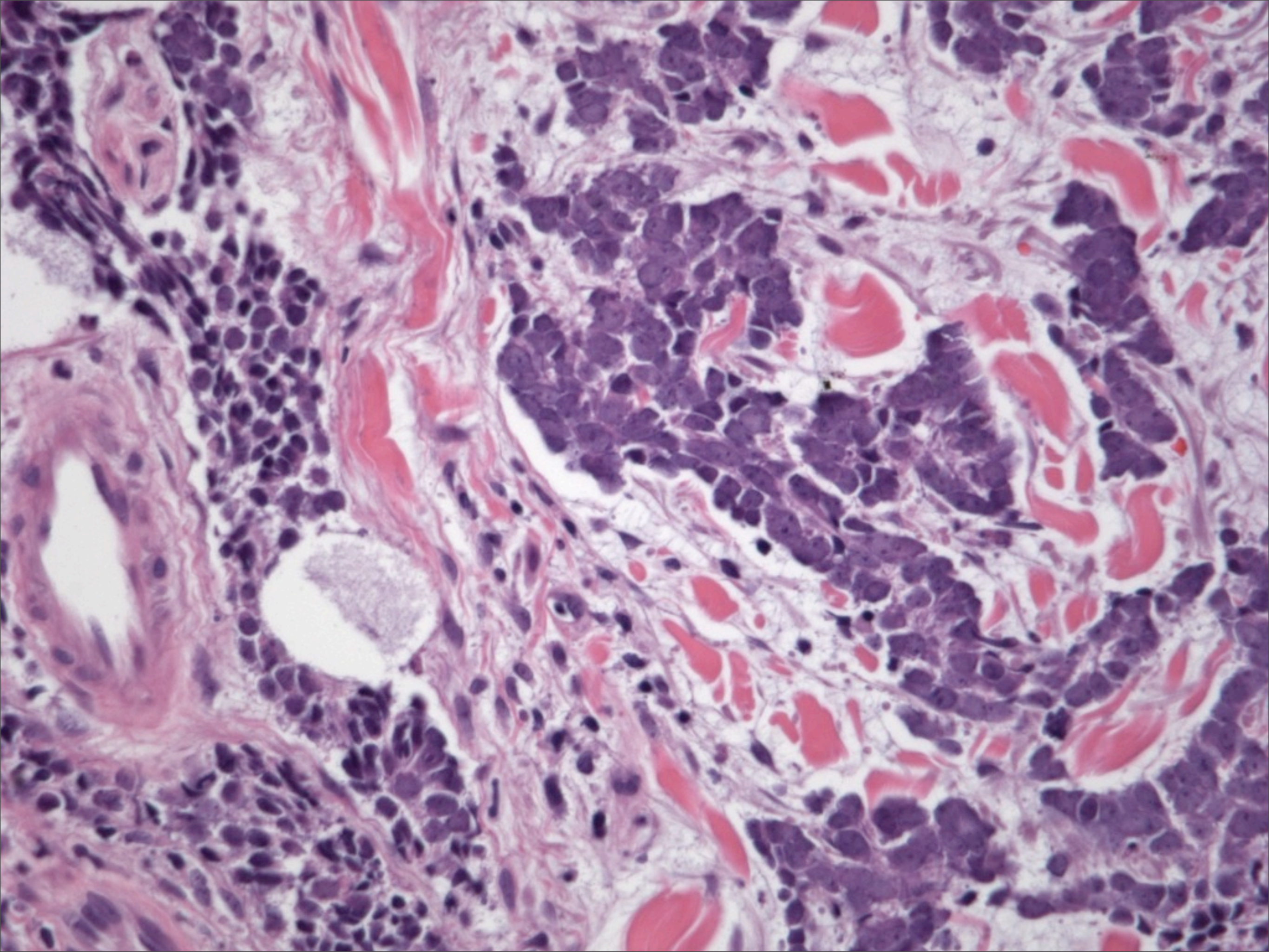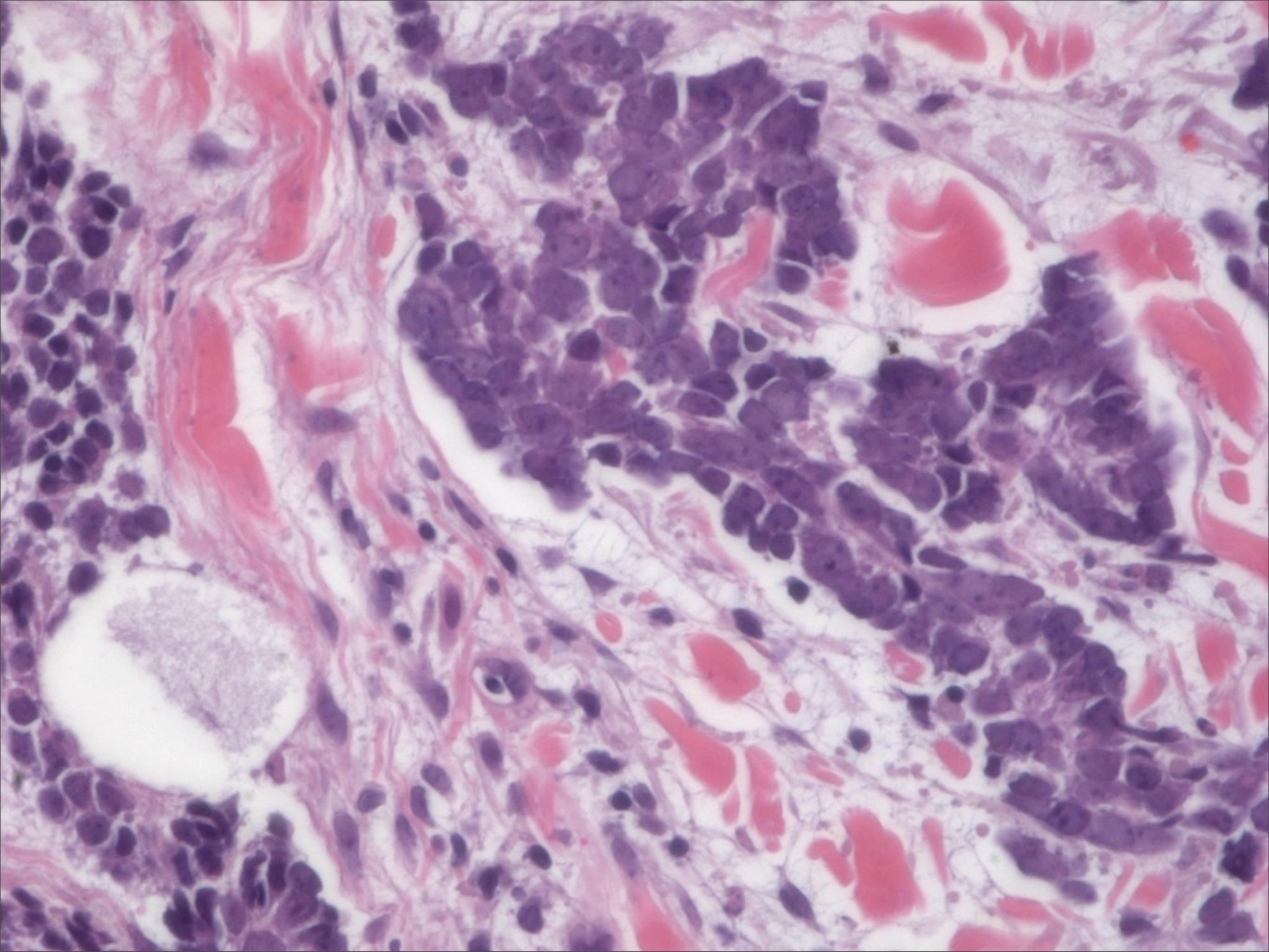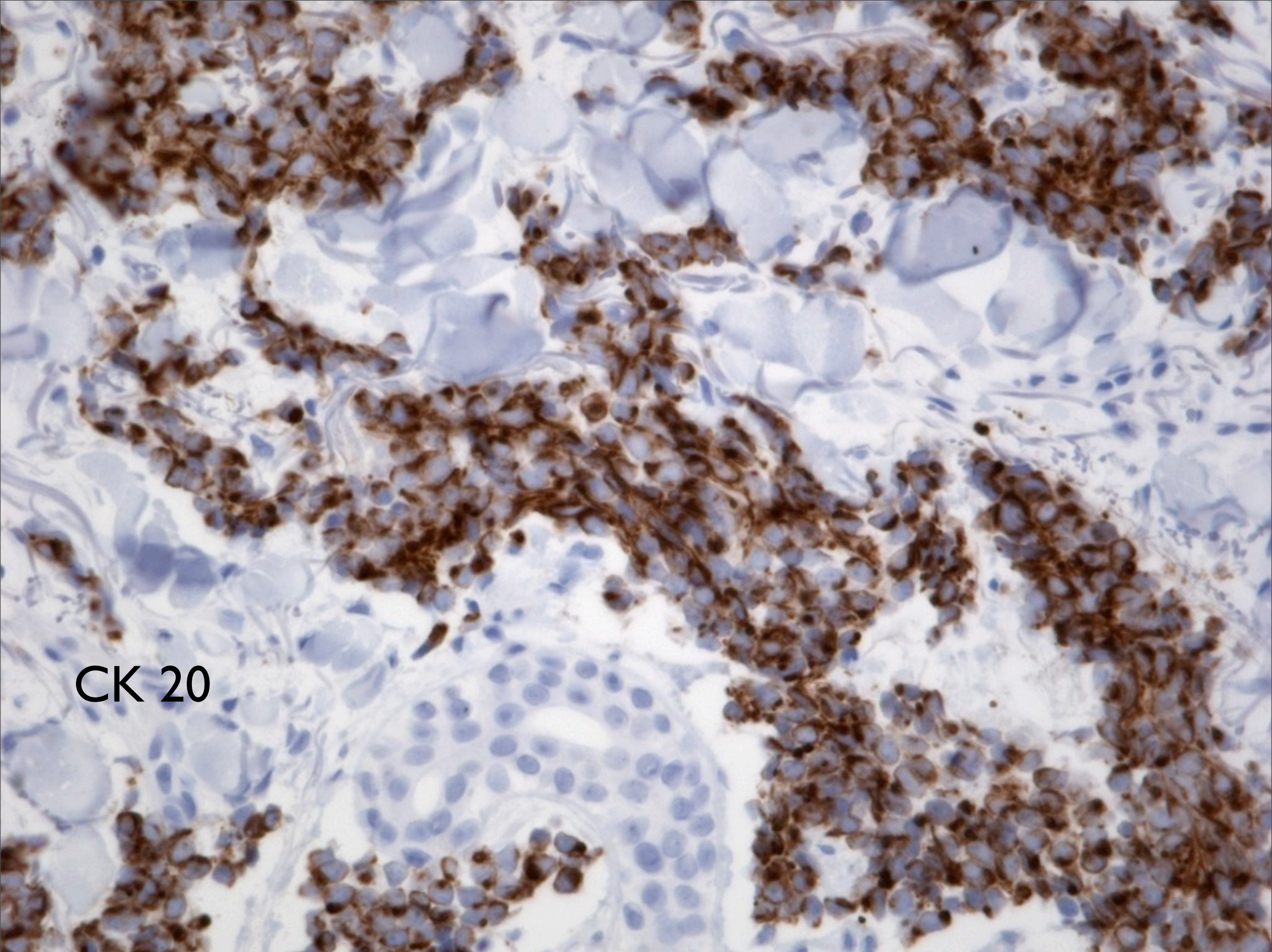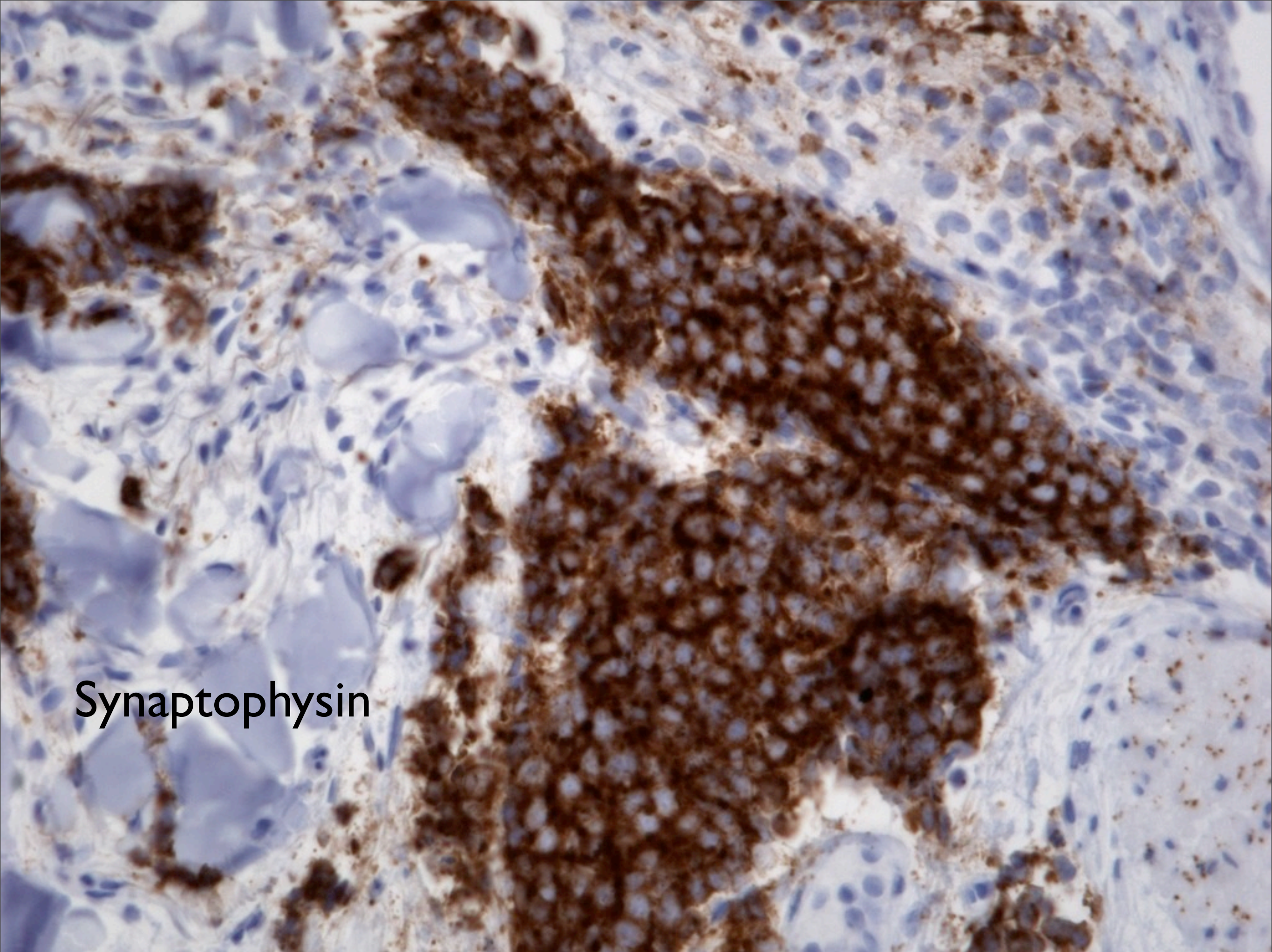
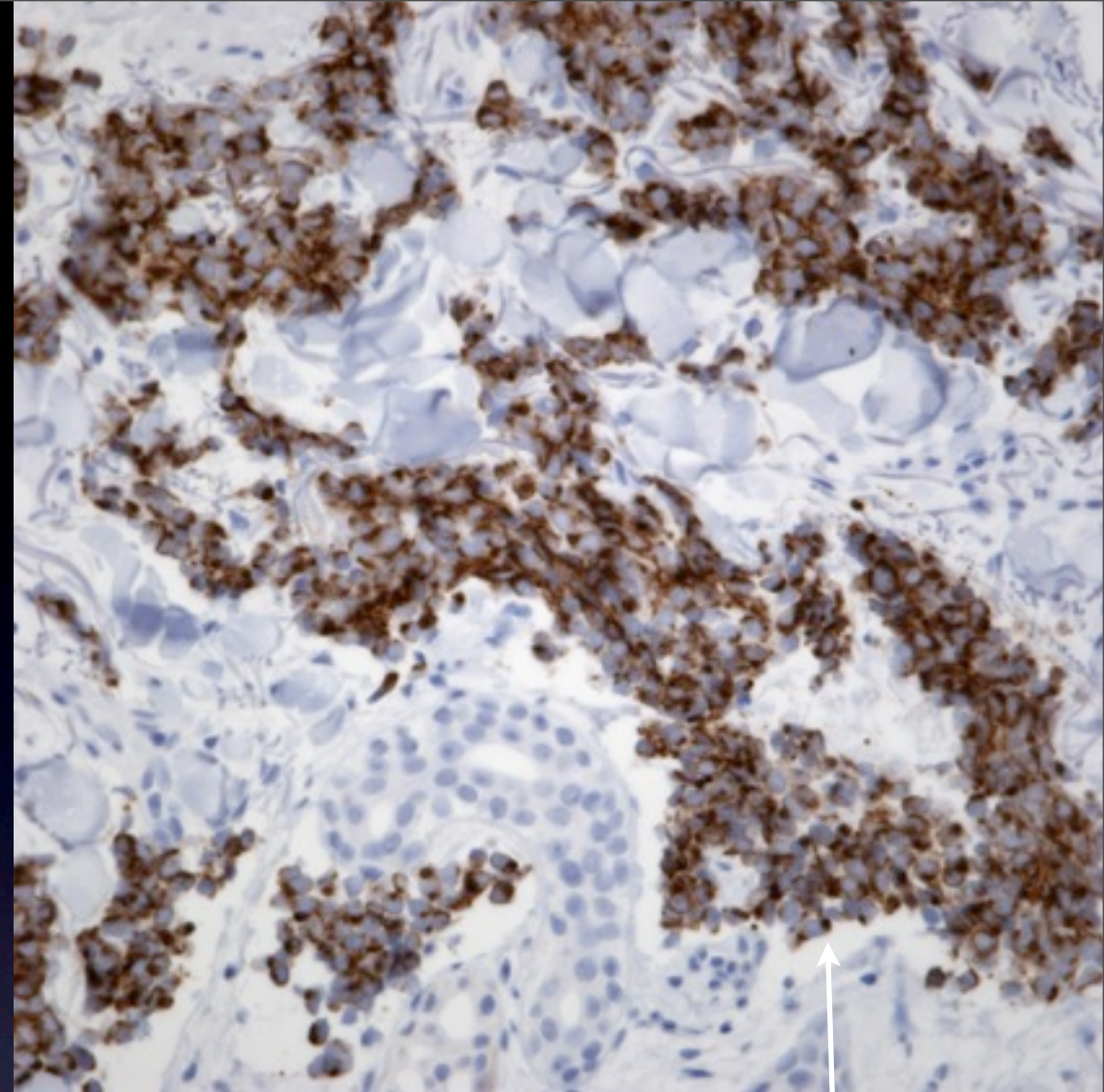
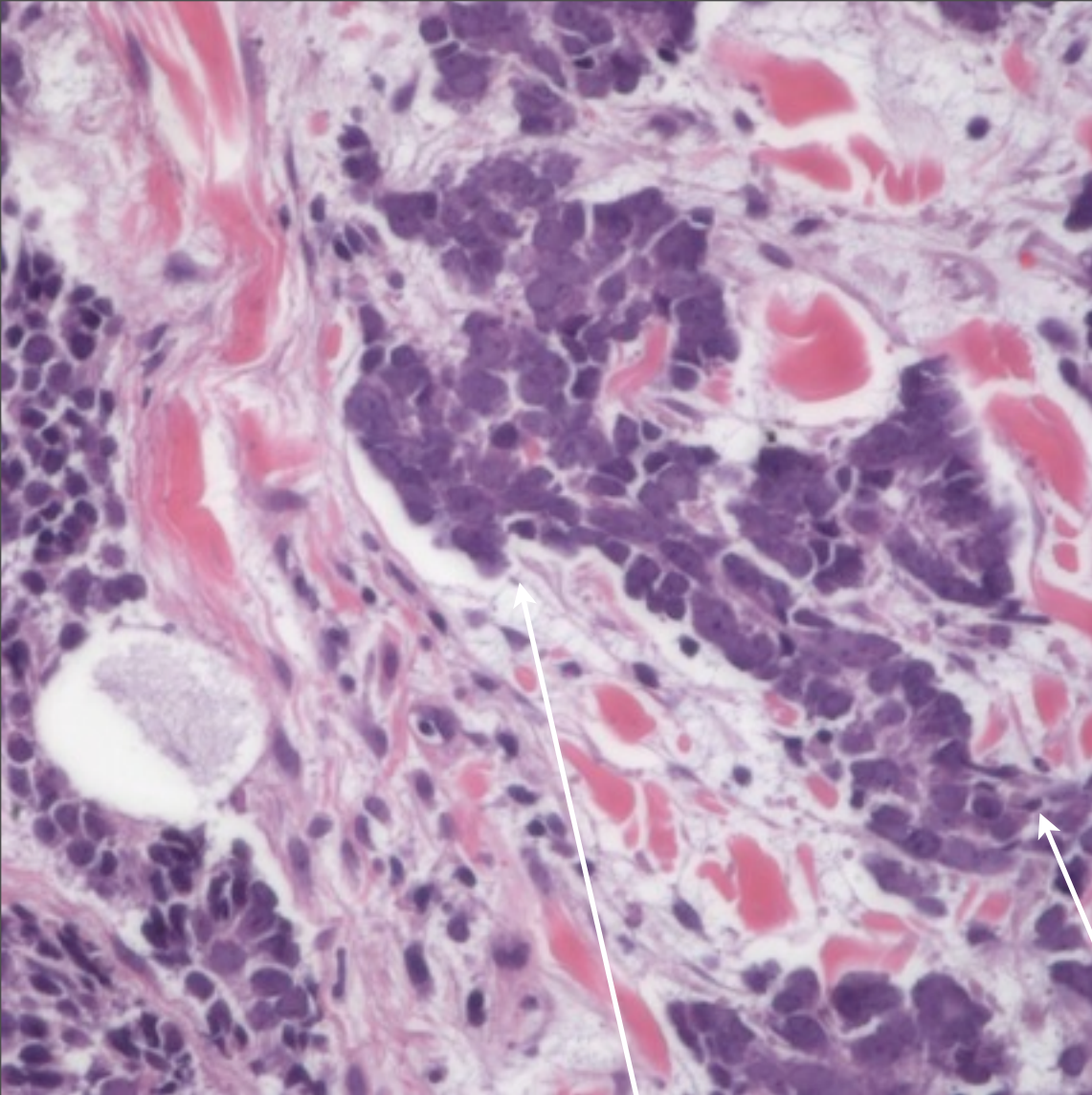


CK 20



Synaptophysin

Merkel Cell Carcinoma



Hyperchromatic round cells with nuclear molding

Stippled nuclear chromatin

Paranuclear Dot-like positivity for Cytokeratin

Rule out metastatic neuroendocrine carcinoma